

## **DYNAMIC CONDYLAR SCREW - CASE STUDY IN CADAVER**

**DR HARVINDER SINGH BALI**

ASSOCIATE PROFESSOR, DEPT OF RACHAN SHARIR, JAMMU INSTITUTE OF  
AYURVEDA AND RESEARCH NARDANI JAMMU

### **Abstract**

A unique variation was noted in upper end of femur bone in 71 years old male cadaver, during a routine dissection class for under graduate Students in jammu institute of Ayurved, jammu (J&K) . In this case, the Dynamic Condylar Screw was placed at subtrochanteric region of femur. Knowledge of such variations is important for subtrochanteric fracture of femur bone for orthopedic surgeons and interventional radiologists. It uses in surgeries like subtrochanteric fracture of femur, distal condylar fractures of femur, correction surgery of failed Dynamic Hip Screw, PFN or femur neck surgeries.

**KEYWORD:** Subtrochanteric fracture, Dynamic Condylar fracture, Dynamic Condylar Screw, Dynamic Hip Screw, Proximal Femur Neck.

### **INTRODUCTION**


Subtrochanteric fractures of the femur account for 10–34% of all hip fractures<sup>1</sup>. These fractures are known to be difficult to treat successfully<sup>2</sup>.

The subtrochanteric region of the femur is mainly cortical due to which the area of healing as well as the vascularity is poorer, prolonging the healing time.

Dynamic condylar screw is an implant assembly that consists of a lag screw, angled barrel plate fixed to the bone [usually distal femur] by 4.5 cortical screws.

DCS and DHS work on the same principle of the sliding nail that allows impaction of the fracture. This is due to the insertion of wide diameter into the condyle [or femoral head]. A side plate, which has a barrel at a fixed angle is slid over the screw and fixed to the femoral shaft.

#### **Parts of Dynamic Condylar Screw**



The barrel plate angle is 95 degrees

Figure: 1

In fact, it has all other components the same as DHS. Just the side plate is different. Plate barrel angle is 95 degrees and plate is shaped to accommodate lateral aspect of the lateral condyle.

### PARTS OF DCS

#### Lag Screw

The lag screw is same as that of dynamic hip screw. The screws are available in various lengths of 50 to 145mm. It has a thread diameter of 12.5mm and a thread length of 22mm. The shaft is slotted [has two flat sides] to fit the barrel and has a length of 8.0 mm. The shaft and barrel slots fit each other so that the screw is able to slide inside the barrel but cannot rotate. On the distal aspect of the shaft of the lag screw, the inner side is threaded. This is for placing compression screw after the screw and plate assembly has been fixed. The purpose of the compression screw is to pull the lag screw towards barrel as the compression screw is tightened 3



Figure: 2

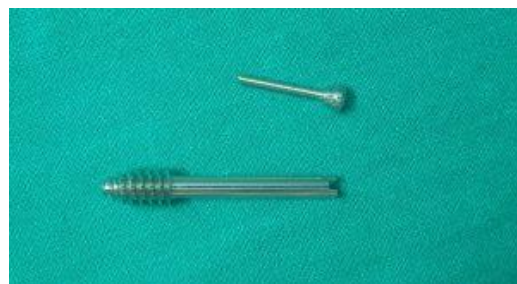

Figure: 3

#### Side plate

The plates are made of 316L stainless steel and are cold-worked for strength. The two holes closest to the barrel accept 6.5 mm cancellous Bone Screws. This enhances stability. Similar to dynamic hip screw, the inside of barrel plate has two flats correspond to the two-flat design of the lag screw. This prevents the rotation of the lag screw within the barrel and eases the insertion too.<sup>3</sup> The DCS plates are available with 6 to 16 holes, for varied clinical situations

### SURGICAL TECHNIQUE:

With the patient lying supine on a traction table, a posterolateral approach was made to the subtrochanteric region. A guide wire was placed on the anterior surface of the femoral neck to determine the anteversion. Another guide pin was inserted across the femoral neck, with due consideration paid to the degree of anteversion and the fixed angle of the implant, such that the tip of the

guide wire was seated 2 cm short of the articular surface in the lower half of the femoral head. An appropriate length condylar screw was then applied over the guide. The condylar screw was engaged in the subchondral bone of the lower quadrant of the femoral head. A suitable side plate was applied after attempting anatomic reduction. At least four screws were applied distal to the main fracture. Minor fragments were lagged in an attempt to restore medial bone support.

In biologically plated fractures reduction was done using the fracture table utilizing skeletal traction. The focus was on obtaining the length, mechanical and rotational alignments. Correct alignment and rotation were checked intraoperatively using X-ray guidance. The length, axial alignment and rotation, were checked again using clinical assessment. Two separate incisions were made. The DCS screw was placed as mentioned from the proximal incision. From the proximal incision the plate was slid across the fracture extraperiosteally with the barrel facing laterally. Once the plate reached the proper length it was rotated and the barrel slid over

the condylar screw. The length of plate chosen was such that the four holes of the plate extended beyond the distalmost extent of the fracture. The plate in this area was exposed by a second incision and fixed to the bone by cortical screws. During the whole procedure the fracture was not exposed. The incision was closed over a suction drain.<sup>4</sup>

Postoperatively, quadriceps exercises were encouraged on the first postoperative day. Range of motion exercises were started within the limits of pain.

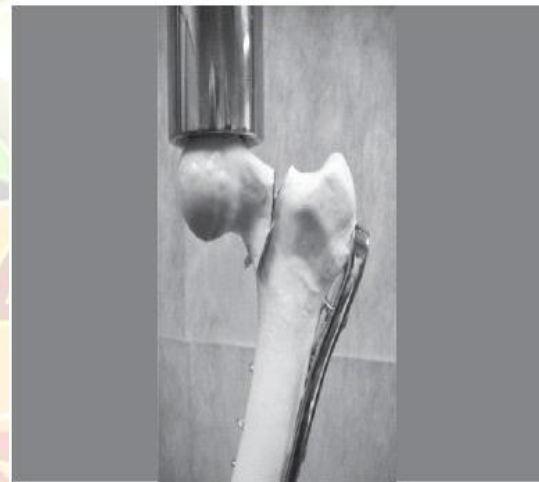


Figure: 4

### **CRITERIA FOR THE ASSESMENT OF RESULT:**

Excellent-  
Flexion loss of less than 10 degrees  
No varus,  
valgus or rotatory deformity  
No pain Perfect joint congruity  
Good-

Minimal pain  
Flexion loss not more than 20 degrees  
Less than 10 degrees varus or valgus deformity  
Loss of length not more than 1–2 cm  
Not more than one of the following

Fair-

Any of the two criteria in the good category

Failure-

Disabling pain

Joint incongruency

Varus or valgus exceeding 15 degrees

Flexion less than 90 degrees<sup>5</sup>

**INDICATIONS:**

Comminuted sub-trochanteric fractures, especially types B and C of the AO classification.

Fracture line extending to piriformis fossa precluding use of an intramedullary device.

Poor general condition, i.e., unable to withstand pro-longed anesthesia as required in open reduction and internal fixation (ORIF)/nailing

**TYPE OF SUB-TROCHENTRIC FRACTURE:**

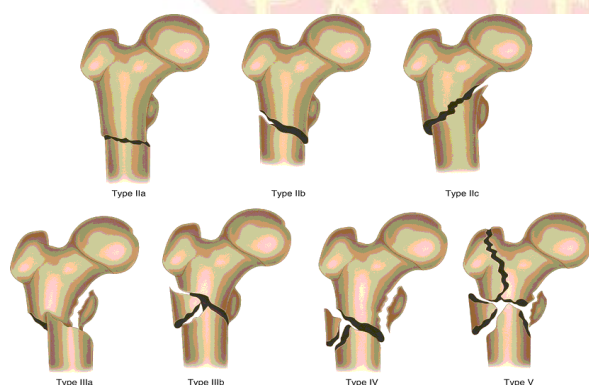


Figure: 5

**CONTRAINDICATION:**

Compound fractures.

Obesity.

Calcar comminution is not a contraindication.

**ADVANTAGE:**

Reduced operating time and blood loss as compared to conventional plating techniques. 6-7

Decrease risk of morbidity and infection. 6

Biologic internal fixation (less rigid fixation, no de-vascularisation of fragments).

Fixation without opening the fracture site in most cases.

Maximal preservation of fracture hematoma, thus enhancing fracture healing.

Formation of periosteal callus, a welcome sign of union as also seen after intramedullary fixation.

Decreased risk of injury to medial perforating vessels from the profunda femoris artery as well as the nutrient artery due to the limited exposure.<sup>8</sup>

Improved rate of union.<sup>6</sup>

Lesser need for bone grafting.

Decreased incidence of non-union, reoperation, and infection 6.

High rotational stability.

**DISADVANTAGE:**

Delayed weight bearing as compared to conventional open reduction and rigid fixation.

Risk of late impaction at the fracture site especially into varus, if early weight bearing is done.

Higher incidence of limb length discrepancy when compared to intramedullary fixation.

Risk of rotational and axial malalignment.<sup>9</sup>

**ERRORS, HAZARDS, COMPLICATION**

Possible errors include –Late impaction/collapse into varus at the fracture site seen especially if the cortical screws in the proximal fragment (calcar screw) are too short, or if the condylar screw is inserted incorrectly.

This requires refixation and bone grafting, rotational and varus/valgus malalignment. Up to 10° varus/valgus and up to 15° rotational deformities are acceptable. Malalignments exceeding these degrees require revision.<sup>10</sup>

**DISCUSSION:**

Dynamic condylar screw is used to fix subtrochanteric fractures of the femur. The insertion point for dynamic

condylar screw on the proximal femur is higher than DHS. Apart from these other steps are similar. The most important factor in management of craniocervical junction injuries is the status of the stabilizing occipitoatlantoaxial ligaments. In the absence of obvious instability ligament disruption, most occipital condyle fractures are managed non-operatively with external stabilization. Isolated unstable fracture may be treated by posterior occipitocervical fusion. When considered according to Anderson and Montesano types. The exact nature of the fracture should be determined before surgical intervention and all major fracture fragments should be identified. Preoperative planning allows one to determine optimum placement of the entry point and determine the appropriate lengths of the blade and side plate. After exposure through a lateral incision on the distal femur, the fractures are temporarily stabilized with k-wires and guidewires. If required cancellous screws are used to fix the small intercondylar fragment.

**CONCLUSION:**

Dynamic condylar screw is used to fix subtrochanteric fractures of the femur. It has advantages like Decrease risk of

morbidity and infection, Reduced operating time and blood loss with less disadvantages. It is contraindicated in Compound fractures, Obesity.

**REFERENCES:**

1. Lavelle David G (2003) Campbells operative orthopaedics, 10th edn. Mosby, St. Louis, p 2897.
2. Asher MA, Tippet JW, Rockwood CA, Zilber S (1976) Compression fixation of subtrochanteric fractures. CORR No 117: June [PubMed].
3. <https://boneandspine.com/dynamic-condylar-screw/Indications and Procedure-BY DR ARUN PAL SINGH>.
4. Technique of Biologic Fixation of Subtrochanteric Femoral Fractures with Dynamic Condylar Screw (DCS)\_December 2002\_Orthopaedics and Traumatology 10(4):310-318\_\_DOI: 10.1007/s00065-002-1059-3\_\_Project: Subtroch  
[HYPERLINK "https://www.researchgate.net/project/Subtroch-Fractures"](https://www.researchgate.net/project/Subtroch-Fractures)anterior  
[HYPERLINK "https://www.researchgate.net/project/Subtroch-Fractures"](https://www.researchgate.net/project/Subtroch-Fractures) Fractures
5. The dynamic condylar screw in the management of subtrochanteric fractures: does judicious use of biological fixation enhance overall results? Manzoor [HYPERLINK "https://www.ncbi.nlm.nih.gov/pubmed/?term=Halwai%20MA%5BAuthor%5D&cauthor=true&cauthor\\_uid=18427748"](https://www.ncbi.nlm.nih.gov/pubmed/?term=Halwai%20MA%5BAuthor%5D&cauthor=true&cauthor_uid=18427748)Ahmed [HYPERLINK "https://www.ncbi.nlm.nih.gov/pubmed/?term=Halwai%20MA%5BAuthor%5D&cauthor=true&cauthor\\_uid=18427748"](https://www.ncbi.nlm.nih.gov/pubmed/?term=Halwai%20MA%5BAuthor%5D&cauthor=true&cauthor_uid=18427748)Halwai, Shabir Ahmed Dhar, Mohammed Iqbal [HYPERLINK "https://www.ncbi.nlm.nih.gov/pubmed/?term=Wani%20MI%5BAuthor%5D&cauthor=true&cauthor\\_uid=18427748"](https://www.ncbi.nlm.nih.gov/pubmed/?term=Wani%20MI%5BAuthor%5D&cauthor=true&cauthor_uid=18427748)Wani, Mohammed Farooq Butt, Bashir Ahmed Mir, Murtaza Fazal Ali, and Imtiyaz Hussain Dar\_\_Copyright © Springer-Verlag 2007.
6. Kinast C, Bolhofner BR, Mast JW, Ganz R. Subtrochanteric fractures of the femur. Results of treatment with 95° condylar blade plate. Clin Orthop 1989;238:122–30.
7. Nungu KS, Olerud C, Rehnberg L. Treatment of subtrochanteric fractures with the AO dynamic

- condylar screw. Injury 1993;24: 90–2.
8. Krettek C, Schandelmaier P, Mclau T, Tscherne H. Minimally invasive percutaneous plate osteosynthesis (MIPPO) using the DCS in proximal and distal femoral fractures. Injury 1997;28:Suppl 1: S-A20–30.
9. Krettek C, Mclau T, Grun O, Schandelmaier P, Tscherne H. Intraoperative control of axes, rotation and length in femoral and tibial fractures – technical note. Injury 1998;29:Suppl 3:S-C29–39.
10. Siebenrock KA, Muller U, Ganz R. Indirect reduction with a condylar blade plate for osteosynthesis of subtrochanteric femoral fractures. Injury 1998;29:Suppl 3:S-C7-1.

**Corresponding author:**

**DR HARVINDER SINGH BALI**

Associate Professor, Department of Rachana sharir, Jammu Institute of Ayurveda and Research, Nardani Jammu.

**Email:** [drharvindarsinghbali.8@gmail.com](mailto:drharvindarsinghbali.8@gmail.com)

**Source of Support: NIL**  
**Conflict of Interest : None declared**

**Published BY:**  
*Shri Prasanna Vitthala Education and Charitable Trust (Reg)*

**PARYESHANA**