

## **A CASE REPORT ON TRAUMATIC TYMPANIC MEMBRANE PERFORATION (TTMP) AND IT'S MANAGEMENT THROUGH AYURVEDA.**

**Dr.TarunKumar Dwibedi<sup>1</sup>,Dr.Veerayya R Hiremath<sup>2</sup>, Dr. Shashikala K<sup>3</sup>,Dr. Gururaj N.<sup>4</sup>**

<sup>1</sup>P.G Scholar, <sup>2</sup> Professor and HOD, <sup>3</sup> Asso. Professors, <sup>4</sup> Asst. Professors. Dept.

Shalakya Tantra SJGAMC, KOPPAL

DOI: <https://doi.org/10.47071/pijar.2020.v05i06.009>

### **ABSTRACT**

Traumatic Tympanic membrane Perforation (TTMP) is an *Agantuja Vrana* or *Agantuja Karna Roga*. The traumatic perforation can be caused by a physical blow to the ear (such as a collision or slap), blast, barotrauma (pneumatization of the mastoid cells) or insertion of sharp objects (such as cotton swabs, bobby pins and sticks). Moreover, some previous studies have shown that the injury occurs more often in the left ear than the right. The patient always suffers reversible high-frequency deafness, occasionally complicated with tinnitus and vertigo. Most TTMPs (about 80%) can heal spontaneously within 3 months post injury. However, large perforations usually fail to close, and appropriate treatment should be performed to reduce the incidence of permanent impairment. In *Agantuja-Vrana*, *shamana* and *Sodhana chikitsa* were adopted according to *Ayurved*. In *Ayurvedic* literature, there is no direct reference of TTMP. Therefore, it is a challenge for us to treat the condition with the treatment modalities of *Ayurveda*. However, result of the case study shows the real potency of *Ayurveda*. The local as well as systemic Medication in the form of *Kushtadi Taila KarnaPichu* and *Shadanga Guggulu* respectively, shows their Rapid rate of recovery in terms of Closure of the Perforation within 5 Days. Here the *Lekhana, Vrana Ropana, Vrana Sodhana, Rasayana, Krimighna, Soolahara* and *Sweda Janana* Property of the drugs present in *Kushtadi Taila Karna Pichu* and *Shadanga Guggulu* Come in to act and perform the rapid Healing mechanism.

**Key words:** *Traumatic Tympanic Membrane Perforation, Kushtadi Taila, KarnaPichu, Shadanga Guggulu.*

## **INTRODUCTION**

Acharya of Brihatrayee, Laghutrayee and many Scholars of Ayurved clearly mentioned Nidana of KarnaRoga. Mithyayoga of Shashtra is one of the causes of KarnaRoga [1]. Physical blow to the ear (such as a collision or slap), blast, barotrauma (pneumatization of the mastoid cells) or insertion of sharp objects (such as cotton swabs, bobby pins and sticks) [2- 4]. Among these, collision is more often the cause in males, while perforation induced by insertion of a cotton swab is approximately twice as common in females [3]. Moreover, some previous studies have shown that the injury occurs more often in the left ear than the right [3, 5, 6]. *Mithyayoga of Shashtra* is the trauma causing injury to the wall of external auditory canal or perforation to the tympanic membrane. We can co-relate this condition to the TTMP as Agantuja Vrana. TTMP patients always suffer reversible high-frequency deafness, occasionally complicated with tinnitus and vertigo [3, 7, 8]. Most TTMPs (about 80%) can heal spontaneously within 3 months post injury [4, 5, 9-12]. However, large perforations usually fail to close, and appropriate treatment should be performed to reduce the

incidence of permanent impairment [10, 12-15] .

Ayurved is the natural healer. Since thousands of years, Ayurved is adopted as the remedy of many acute and chronic diseases. Scholars of Ayurved have been mentioned many Bhesaja (medicines) in the form of Vati, Choorna, Kwatha, Swarasa, Bhasma, Taila, Ghrita, Leha etc. and many Chikitsa Upakrama (therapy) in the form of Panchakarma (Snehana, Swedana, Vamana, Virechana, Nashya, Rakta Mokshyana and Basti Karma). The topical treatment, that is local application of drugs or *Sthanika Chikitsa* in the form of Avyanga, Swedana, Lepa, Netra Tarpana, Karna Poorana, Ksharakarma, Agnikarma, Raktamokhna and Sansamana Chikitsa is mentioned in different classical literatures.

*KarnaPichu* is a modified form of *Karnapoorana*, which provides a long duration of skin contact time with controlled release of the Drugs. The Kushtadi Taila<sup>[16, 17]</sup> was used in this Agantuja Vrana (TTMP) as KarnaPichu and the Shadanga Guggulu Kwatha<sup>[18]</sup> mentioned in Chakradatta, was used in the form of tablet as Sansamana Chikitsa to reduce the Sotha and Soola in TTMP and this study just after 5<sup>th</sup> day of

## A CASE REPORT ON TRAUMATIC TYMPANIC MEMBRANE PERFORATION (TTMP) AND IT'S MANAGEMENT THROUGH AYURVEDA

treatment shows marked improvement in the perforation of tympanic membrane.

### MATERIALS AND METHOD

#### Case report

A 26 years old male patient complaining reduced hearing and mild pain in left ear since 7 days with H/O hit on left cheek and mechanical trauma to left ear (non-MLC) visited the OPD of SJGAMC & H, Koppal vide Registration No. 89215/ Dt. 1.11.2019. No history of bleeding or discharge from the ear.

#### Examination of the Patient

Otoscopic Examination of the left ear shows a 2mm\*4mm oval shaped central Perforation with 3-4 hemorrhagic lesions with irregular edges. In Rinne's test, it was found that BC > AC in left ear, representing conductive deafness, whereas the right ear was normal. Webber's test also reveals conductive deafness of the Left ear. After careful examination of the patient and his

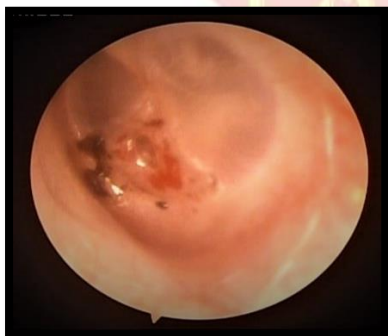history, the patient was diagnosed as Traumatic Tympanic Membrane Perforation (TTMP).

#### Procedures administered to the patient

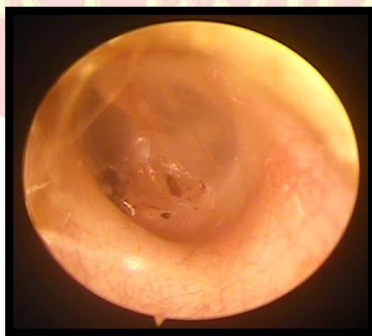
Patient was administered with Kushtadi Taila as Karna Pichu twice daily for 7 days and Tab. Shadanga Guggulu 500mg 1tab twice daily for 15 days. Follow Up was made on Day 15.

#### RESULTS

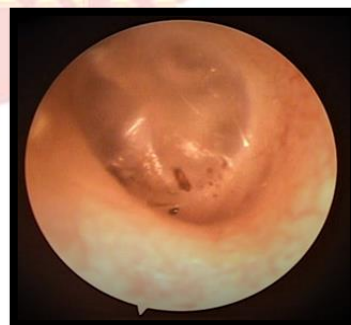- On day three, the dimension of perforation was reduced from 2mm\*4mm to 1mm\*1.5mm. And there is very little pain in the Ear which probably due to the cotton Pichu inserted in the EAC
- On Day five, the Perforation was closed.
- On day seven, the perforation was totally closed and there was no pain. Patient's hearing was restored.
- On Day fifteen Tympanic, membrane was clear and no mark of perforation was found.



DAY 1



DAY 5



DAY 15

Fig. showing the Tympanic membrane on day 1, 5 and 15

## **DISCUSSION**

The Tympanic membrane has three distinct layers <sup>[19]</sup>, the Outer epithelial layer, which is the continuation of the skin of EAC, the Middle most fibrous layer, which has radial, circular and parabolic fibrous layer and the inner most mucosal layer, which continues as the mucosal layer of middle ear cleft.

However, in 1851 **Toynbee** demonstrated that the Pars Tensa of TM has five layers <sup>[20]</sup>:-

1. Outer epidermis
2. Dermis of fibrous tissue ,blood vessels and nerves
3. Outer radial fibrous
4. Inner circular fibrous
5. Innermost thin mucosal layer

Histopathological study of a newly formed perforation shows proliferation of squamous epithelium within 12 hours at the edge of the perforation and granulation formation within 18hrs, while the inner mucosa of the tympanic membrane takes several days to regenerate <sup>[21]</sup>. In chronic tympanic membrane perforation, squamous epithelium is found adjacent to the middle ear mucosa and creates a perforation edge with no raw surface. This is a contributing factor for a perforation to persist and was observed

by Dunlop and Schuknecht in 1947<sup>[22]</sup>.

The squamous epithelial layer of the perforated edge of tympanic membrane ceases closure of the TTMP.

Usually most of the TTMP heals spontaneously within 3 month of injury <sup>[4, 5]</sup>. Large perforations usually fail to close and need specific measures to get rid of the impairment <sup>[10, 12]</sup>. There are few non-surgical methods to induce closure of the perforation. Those are irritant oils <sup>[23]</sup>, fibrin glue <sup>[23]</sup>, fat plug <sup>[24]</sup>, carbon Dioxide Laser trimming of the Margins before applying paper patch <sup>[25]</sup> etc. Studies have shown that moisture balance is important during wound healing and a moist environment facilitate cellular growth and collagen proliferation with in a healthy non cellular matrix, There by hastening the healing of both acute and chronic wounds and promoting the growth of new tissue<sup>[26, 27]</sup>. Indeed the moist tympanic membrane perforation has been shown to heal rapidly than the dried tympani membrane perforations <sup>[27, 28]</sup>. In acidic medium the healing mechanism of tympanic membrane perforation is rapid than in Alkaline medium <sup>[29]</sup>.

We have used the Kushtadi taila and Tab. Shadanga Guggulu. The Kushtadi

## A CASE REPORT ON TRAUMATIC TYMPANIC MEMBRANE PERFORATION (TTMP) AND IT'S MANAGEMENT THROUGH AYURVEDA

Taila contains Tila (Sesamum Indicum), Goat urine, Kushta (Saussurea lappa), Hingu (Ferula Narthex), Vacha (Acorus Calamus), Devadaru (Cedrus deodara), Satahva (Anethum sowa), Sunthi (Zinger officinale) and Saindhava (Rock Salt). The Shadanga Guggulu is mentioned in Chakradatta Shadanga Guggulu Kwatha. It is mentioned in Netraroga adhikara as

a Soolahara, Pakahara and Sothahara. It has Amalaki (*Embllica officinalis*), Haritaki (*Terminaliya chebula*), Bibhitaki (*Terminalia bellerica*), leaf of Patola (*Trichosanthes dioica*), bark of Nimba (*Azadirachta indica*), Vasa (*Adhatoda vasika*) and Sudha Guggulu (Commiphora mukul). The property of the drug components are as follows.

### Kushtadi Taila <sup>[16, 17]</sup> :-

NAME	LATIN NAME	PROPERTY
<b>Tila Taila</b>	Sesamum indicum [30]	Vrana Ropaka-Sodhaka, sandhaniya, vedana sthapaka
<b>Kushta</b>	Saussurea lappa [31]	Vedana sthapaka , Rasayana, jantughna
<b>Hingu</b>	Ferula Narthex [32]	vedana sthapaka , jantughna
<b>Vacha</b>	Acorus Calamus [33]	Sweda janana, vedana Hara, Sothahara
<b>Devadaru</b>	Cedrus deodara <sup>[34]</sup>	Sweda janana, Lekhana, Sothahara, vedana hara, krimighna
<b>Satahva</b>	Anethum sowa [35]	Karna soola hara
<b>Sunthi</b>	Zinger officinale [36]	Sothahara, vedana sthapaka, srotasodhaka
<b>Saindhava</b>	Rock salt [37]	Tridosahara, Wound healing activity <sup>[38]</sup>
<b>Aja Mutra</b> <sup>[39, 40]</sup>	-----	Karna soola hara, sofa hara

### Shadanga Guggulu <sup>[18]</sup>:-

NAME	LATIN NAME	PROPERTY
<b>Ghee</b>	Ghee [37]	Rasayana
<b>Guggulu</b>	Commiphora mukul [41]	Lekhana-Rasayana-Ropaka-Vedana Sthapaka
<b>Amalaki</b>	<i>Embllica officinalis</i> [42]	Rasayana- Indriya

**A CASE REPORT ON TRAUMATIC TYMPANIC MEMBRANE PERFORATION (TTMP) AND IT'S MANAGEMENT THROUGH AYURVEDA**

<b>Haritaki</b>	<i>Terminaliya chebula</i> [43]	Vrana Ropaka-Sodhaka-Rasayana-Indriya
<b>Bibhitaki</b>	<i>Terminalia bellerica</i> [44]	Vrana Ropaka-Sodhaka
<b>Vasa</b>	<i>Adhatoda vasika</i> [45]	Vedana Sthapaka-Sothahara-KhyayaNasaka
<b>Nimba</b>	<i>Azadirachta indica</i> [46]	Vrana Ropaka-Sodhaka, Khyaya Hara
<b>Patola</b>	<i>Trichosanthes dioica</i> [47]	Vedana Sthapaka, Vrana Ropaka-Sodhaka

*Kushtadi Taila* is indicated in *Puti-Karna*. *Puti Karna* can be co related with CSOM. In CSOM, there is a permanent perforation in the tympanic membrane. The ingredient of *Kushtadi taila* has the property of *Sandhaniya (Tila Taila) Vrana Ropaka and Sodhaka (Tila, Sunthi), Sothahara (Vacha, Devadaru, and Sunthi), Vedana Sthapaka (Kushta, Devadaru, Vacha, Sathva, and Sunthi), Sweda janana (Vacha, Devadaru), Krimighna / Jantughna (Hingu, Devadaru), Rasayana (Kushta, Saindhava) and Vrana Ropana karma i.e.* wound healing activity [38].

The Human cell membrane is Lipophilic as it is biphospolipid [48]. The lipids or the lipid soluble drugs can enters through the biphospolipid layer through the Passive diffusion [48]. In addition, the water-soluble particle through the Para cellular space or the aqueous pores present in the cell membrane [49]. Therefore, the lipid soluble part and the aqueous soluble parts of the *Kushtadi*

*taila* can easily enters in to the cell through the cell membrane, to the cytoplasm and hence to the tissue of external auditory canal (EAC) .

In the context of netra-Kriyakalpa, it has been told that, the drugs of the Kriyakalpa absorbs through the Vartma (skin of the lid), Sandhi (through the junctional area of eye) Sirakosha (orbital surface), *sira* (blood vessels)<sup>[50]</sup>. *Astanga Sangraha and Hridaya Kara* stated that the drugs are absorbed through the capillaries (*Srotas*) of *Kasha Sandhi* that is through the hair follicle, through the *Ghrana* that is through the nasal mucosa, through the *Ashya* that is through the oral mucosa [51, 52]. That mode of action of the Kriyakalpa suggests that the drugs are absorbed through the skin in contact, through the blood capillaries, through the hair follicles and through the mucosal membrane. Thus, the drugs of *Karna pichu* are absorbed by the skin, hair follicles and through the capillaries beneath the skin.

## A CASE REPORT ON TRAUMATIC TYMPANIC MEMBRANE PERFORATION (TTMP) AND IT'S MANAGEMENT THROUGH AYURVEDA

There it reaches the cell organelles. It provides nutrition and stimulates the cell organelles. Therefore, it restores the function of tissues by rejuvenating them. We are using the medicated oil in form of *Pichu* (a cotton roll soaked in Medicated oil), so there is more contact time of the oil, which provides better absorption of the drug in EAC and in Tympanic Membrane.

Shadanga Guggulu is indicated in *Sofa and Paka mentioned in netra roga*. The ingredients of Shadanga Guggulu suggests *Vrana Ropaka-Sodhaka* (Guggulu, Haritaki, Bibhitaki, Nimba and patola), *Vedana Sthapaka* (vasa, patola), *Rasayana* (Guggulu, Haritaki, Bibhitaki, Ghee and Amalaki), *Indriya* (Haritaki, Amalaki), *Lekhana* (Guggulu) and *Sothahara* (Vasa).

The healing of the perforated tympanic membrane depends on the following factors:-

- Size of the TM [4, 5, 9, 10, 12, 15]
- PH of the medium<sup>[29]</sup>
- Dryness of the medium<sup>[26, 27]</sup>
- Presence of inward grown squamous epithelium <sup>[20]</sup>
- Fibroblastic proliferation and granulation <sup>[20]</sup>
- Circulation to the perforated edges <sup>[20]</sup>

In the above Case, the size of TM is small so it favors the rapid generation of the Tissues. The Kushtadi taila provides Acidic medium, which accelerate the healing mechanism. The ***Sweda janana*** property and the Snigdha Sara Guna of Tila and Guggulu respectively make the Tympanic membrane moisturized. ***Lekhana*** property of the drugs prevents the squamous epithelial layers to cover the edge of the perforation. The ***Khyaya Hara*** property along with ***Rasayana*** provides nutrition, strength and ultimately accelerates the rejuvenation of the Dhatus i.e. epithelial, fibrous and mucosal layers of the TM. That means its favors the fibroblastic proliferation and granulation of the tissues in the perforated edges. ***Vrana Sodhaka-Ropaka-Sandhaniya*** property stimulates the process of healing and favors the flow of blood through the vessels of the TM. ***Indriya*** Property of the drugs provides nutrition and strength to the ***Srotronadi***, which improves Hearing. ***Sothahara*** property reduces ***Sofa*** Caused by the Trauma and ***Vedana Sthapaka*** Property reduced pain.

### SUMMARY

Thousands years ago the Acharyas knew the administration of drugs in various

## A CASE REPORT ON TRAUMATIC TYMPANIC MEMBRANE PERFORATION (TTMP) AND IT'S MANAGEMENT THROUGH AYURVEDA

routes as *Oushadha Sevana, Vasti, Abhyanga, Lepa, Shirodhara, Pratisarana, Tarpana, Anjana, Aschyatono, Bidalaka, Karnapoorana, Kabala, Gandusha, Nashya, Dhoomapana etc.* They knew the drug entry through the *Sirakosha* (hair root), *sira* (blood vessels), which is mentioned in the context of *Netra Kriyakalpa*. It shows the level development in Ancient Ayurveda. The *KarnaPichu* is a modified form of *Karnapoorana*, which provides more contact time causing slow absorption of drug for a long period. Thus favoring the condition, which is required for the rapid healing procedures in Perforation of Tympanic membrane. The traumatic edge of the perforation heals rapidly as it does not have the ingrown mucosal layer. The rejuvenation of the *Dhatu* and the cell organelles by the local application of the *Pichu* promotes the Fibroblastic proliferation and granulation at the edge of the perforation. The irritant, *Kushtadi Taila* and the *Shadanga Guggulu* promotes the circulation, reduces *Sofa* and prevents *Paka*. Hence, the Environment all around the TTMP, promotes the rapid healing.

### CONCLUSION

Agantuja Vrana are caused by injury or trauma. The Vata, Pitta, Kapha

Separately or by combination are involved in different stages of Agantuja Vrana. Traumatic Tympanic membrane Perforation (TTMP) is an *Agantuja Karna Vrana*. Considering the Nidana, Dosha-*Dhatu-Adhithana* and Chronicity of the disease, the Chikitsa Sutra (treatment protocol) are developed or modified. Now a days People of the modern era need rapid recovery and the medical sciences, which provides a rapid rate of recovery, wins the race of treatment. Considering all the chikitsa sutra the above treatment modalities were adopted. Those treatment modalities prevented complication and secondary infection. It prevents the delay of healing and plays the role of a rapid healer. Thus, the treatment validates the potency of Ayurved. Therefore, the combination of Kushtadi-Taila KarnaPichu along with Shadanga Guggulu can be taken to treat tympanic membrane perforations.

### REFERENCE

1. Sastri Laksmipati, Yogaratnakara with Vidyotini Hindi Commentary, Published by Chaukhambha Prakashan, Varanasi, reprint 2010, Uttarardha, KarnaRoga Adhikara P.309.
2. Aktaş D, Kutlu R (2000) The relationship between traumatic tympanic membrane



## **A CASE REPORT ON TRAUMATIC TYMPANIC MEMBRANE PERFORATION (TTMP) AND IT'S MANAGEMENT THROUGH AYURVEDA**

- perforations and pneumatization of the mastoid. *ORL J Otorhinolaryngol Relat Spec* 62(6): 311-315.
3. Hempel JM, Becker A, Müller J, Krause E, Berghaus A, Braun T (2012) Traumatic tympanic membrane perforations: Clinical and audiometric findings in 198 patients. *Otol Neurotol* 33(8): 1357-1362.
  4. Lou ZC, Lou ZH, Zhang QP (2012) Traumatic tympanic membrane perforations: A study of etiology and factors affecting outcome. *Am J Otolaryngol* 33(5): 549-555.
  5. Chun SH, Lee DW, Shin JK (1999) A clinical study of traumatic tympanic membrane perforation. *Korean Journal of Otolaryngology-Head and Neck Surgery* 33(5): 853-862.
  6. Kim CN (1986) Effect of the cellophane prosthesis to the traumatic tympanic membrane perforation. *The Ewha Medical Journal* 9: 197-205.
  7. Hussain S (1995) Hearing loss in the 4-8 kHz range following tympanic membrane perforation from minor trauma. *Clin Otolaryngol Allied Sci* 20(3): 211-212.
  8. Pusz MD, Robitschek JM (2013) Traumatic hearing loss in the context of blast-related tympanic membrane perforation. *Mil Med* 182(1): e1645-e1648.
  9. Yamazaki K, Ishijima K, Sato H (2010) A clinical study of traumatic tympanic membrane perforation. *Nihon Jibiinkoka Gakkai Kaiho* 113(8): 679-686.
  10. Al-Juboori AN (2014) Evaluation of spontaneous healing of traumatic tympanic membrane perforation. *General Medicine* 2: 1000129.
  11. Kristensen S (1992) Spontaneous healing of traumatic tympanic membrane perforations in man: A century of experience. *J Laryngol Otol* 106(12): 1037-1050.
  12. Orji F, Agu C (2008) Determinants of spontaneous healing in traumatic perforations of the tympanic membrane. *Clin Otolaryngo* 33(5): 420- 426.
  13. Griffin WL (1979) A retrospective study of traumatic tympanic membrane perforations in a clinical practice. *Laryngoscope* 89(2): 261- 282.
  14. Armstrong BW (1972) Traumatic perforations of the tympanic membrane: Observe or repair? *Laryngoscope* 82(10): 1822-1830.
  15. Jellinge M, Kristensen S, Larsen K (2015) Spontaneous closure of traumatic tympanic membrane perforations: Observational study. *J Laryngol Otol* 129(10): 950-954.

**A CASE REPORT ON TRAUMATIC TYMPANIC MEMBRANE PERFORATION (TTMP) AND IT'S  
MANAGEMENT THROUGH AYURVEDA**

---

16. Sastri AmbikaDatta, Bhaishajya Ratnavali, Edited By Mishra Brahma Shankar, Published By Chaukhambha Sanskrit Sansthan, Varanasi, Reprint 2014, Vol. III, 62/42, P. 239.
17. Tripathi Indradeva, Chakradatta with Vaidayaprabha Hindi Commentary, Published by Chaukhambha Sanskrit Sansthan, Varanasi, Reprint 1997, KarnaRoga Chikitsa Shloka No.52, P.342.
18. Tripathi Indradeva, Chakradatta with Vaidayaprabha Hindi Commentary, Published by Chaukhambha Sanskrit Sansthan, Varanasi, Reprint 1997, Netraroga Adhikara 59/42-43, P. 351.
19. Dhingra P.L., Disease of Ear, Nose and Throat, Jaypee Brother Medical Publishers, Fifth Edition, 2010 P. 4.
20. T. Santhi, K.V.Ranjan, A Study Of Closure Of Tympanic Membrane By Chemical Cauterisation, Indian J Otolaryngol Head Neck Surg, Springer, October-December 2012, 64(4):389-392.
21. Gulya AJ, Glasscock ME (2003) Glasscock, Shambaugh surgery of the ear, 5th edn. BC Decker Inc, Spain, pp 400-420.
22. Shambaugh GE (1967) Glasscock, Shambaugh surgery of the ear, 2nd edn. W.B. Saunders Company, Philadelphia, pp 429-437.
23. Dorsun E (2008) Comparison of paper-patch, fat, and perichondrium myringoplasty in repair of small tympanic membrane perforations. Otolaryngol Head Neck Surg 138:353-356
24. Upal KS (1997) Closure of tympanic membrane perforation by chemical cautery. IJOL HNS 49:151-153
25. Lee SH, Lee KC et al (2008) Paper patch myringoplasty with carbon dioxide laser for chronic tympanic membrane perforations. Eur Arch Otorhinolaryngol 265:1161-1164
26. Okan D, Woo K, Ayello EA, Sibbald G (2007), The role of moisture balance in wound healing. Adv Skin Wound Care 20(1): 39-53.
27. Schultz GS, Sibbald RG, Falanga V, Ayello EA, Dowsett C, et al. (2003) Wound bed preparation: A systematic approach to wound management. Wound Repair Regen 11: S1-28.
28. Lou Z, Wang Y, Su K (2014) Comparison of the healing mechanisms of human dry and endogenous wet traumatic eardrum perforations. Eur Arch Otorhinolaryngol 271(8): 2153-2157.
29. Akkoc A, Celik H, Arslan N, Demirci S, Hucumenoglu S, et al. (2016) The effects of different environmental pH on healing of tympanic membrane: An experimental

**A CASE REPORT ON TRAUMATIC TYMPANIC MEMBRANE PERFORATION (TTMP) AND IT'S  
MANAGEMENT THROUGH AYURVEDA**

- study. Eur Arch Otorhinolaryngol 273(9): 2503-2508.
30. Sharma P.V. Dravyaguna Vijnana- published by Chaukhambha Bharati Academy; Varanasi; Reprint 2017, P.121.
31. Sharma P.V. Dravyaguna Vijnana- published by Chaukhambha Bharati Academy; Varanasi; Reprint 2017, P.573
32. Sharma P.V. Dravyaguna Vijnana- published by Chaukhambha Bharati Academy; Varanasi; Reprint 2017, P.350
33. Sharma P.V. Dravyaguna Vijnana- published by Chaukhambha Bharati Academy; Varanasi; Reprint 2017, P.28
34. Sharma P.V. Dravyaguna Vijnana- published by Chaukhambha Bharati Academy; Varanasi; Reprint 2017, P.76
35. Sharma P.V. Dravyaguna Vijnana- published by Chaukhambha Bharati Academy; Varanasi; Reprint 2017, P.403
36. Sharma P.V. Dravyaguna Vijnana- published by Chaukhambha Bharati Academy; Varanasi; Reprint 2017, P.332
37. Sharma Tarachand. Dravya Oushadhi Chart- published by Natha Pusthak Vandar; Varanasi.
38. Ghodela NK, Mahanta V. Dietary regimen for wound healing – An Ayurveda perspective. J Ayurveda Integr Med Sci 2017; 2:154-61.
39. Mitra Jyotir, Astanga Sangraha with Shashilekha Sanskrit commentary by Indu, Third edition, Reprint, 2012, Su.6/106, P. 47.
40. Sashtri AmbikaDutta, Sushruta Samhita with Ayurveda Tattva Sandipika, Hindi commentary, Chaukhambha Sanskrit Sansthan; Varanasi; 2012, Su.45/223, P. 240.
41. Sharma P.V. Dravyaguna Vijnana- published by Chaukhambha Bharati Academy; Varanasi; Reprint 2017, P.55
42. Sharma P.V. Dravyaguna Vijnana- published by Chaukhambha Bharati Academy; Varanasi; Reprint 2017, P.759
43. Sharma P.V. Dravyaguna Vijnana- published by Chaukhambha Bharati Academy; Varanasi; Reprint 2017, P.754
44. Sharma P.V. Dravyaguna Vijnana- published by Chaukhambha Bharati Academy; Varanasi; Reprint 2017, P.239
45. Sharma P.V. Dravyaguna Vijnana- published by Chaukhambha Bharati Academy; Varanasi; Reprint 2017, P.242
46. Sharma P.V. Dravyaguna Vijnana- published by Chaukhambha Bharati Academy; Varanasi; Reprint 2017, P.149
47. Sharma P.V. Dravyaguna Vijnana- published by Chaukhambha Bharati Academy; Varanasi; Reprint 2017, P.697.
48. Tripathy K D, Essentials of Medical

**A CASE REPORT ON TRAUMATIC TYMPANIC MEMBRANE PERFORATION (TTMP) AND IT'S  
MANAGEMENT THROUGH AYURVEDA**

- Pharmacology, Published by Jaypee brothers Medical Publishers (P) LTD, sixth Edition 2008, P. 11-12.
49. Tripathy K D, Essentials of Medical Pharmacology, Published by Jaypee brothers Medical Publishers (P) LTD, sixth Edition 2008, P. 13.
50. Sashtri Ambika Dutta, Sushruta Samhita with Ayurveda Tattva Sandipika, Hindi commentary, Chaukhamba Sanskrit Sansthan; Varanasi; 2012, U.18/54, P. 99.
51. Mitra Jyotir, Astanga Sangraha with Shashilekha Sanskrit commentary by Indu, Third edition, Reprint, 2012, Su.32/6, P. 233.
52. Tripathy Brahmananda, Astanga Hridaya with Nirmala Hindi commentary Chaukhamba Sanskrit Pratishtan; Varanasi; 2017, Su.23/7, P. 264.

**Corresponding author:**

Dr. Tarun Kumar Dwibedi, PG Scholar  
Shree Jagadguru Gavisiddeswara Ayurvedic Medical  
College & Hospital, Koppal, Karnataka, 583231

**Email:** [dr.tarun52@gmail.com](mailto:dr.tarun52@gmail.com)

**Published BY:**

*Shri Prasanna Vitthala Education  
and Charitable Trust (Reg)*

**Source of Support: NIL**

**Conflict of Interest : None declared**