

ROLE OF "RAJANI LEPA" IN THE MANAGEMENT OF ABHAYANTARA ARSHAS W.S.R TO 2ND DEGREE INTERNAL HEMORRHOIDS-CASE REPORT

Savadi B S¹, Hiremath Sangameshwar², Dr Akash Kembhavi³

¹HOD, ²Assistant Professor, ³Professor, Dept of *Shalyatantra*, SJG *Ayurveda* Medical College, Koppal, Karnataka

ABSTRACT:

Arshas or Haemorrhoids are considered to be one of the common ano-rectal problems. Due to junk food habits and sedentary life style, lack of valves in the portal venous system and raised abdominal pressure were thought to contribute to the development of anal varicosities., Often patients come to clinicians when they start pain, bleeding or burning sensation per rectum. Internal Haemorrhoids are one among them. Here In this study patient having signs and symptoms of *abhayantara Arshas* is selected from OPD of SJGAMC Hospital and *RAJANI LEPA* was applied locally with aseptic precaution followed by normal saline wash. Patient is assessed on following parameters such as per rectal bleeding, and size of pile mass. The significant improvement was observed in sign and symptom after treatment.

Keywords: *Abhayantara Arshas* , *RAJANI LEPA* , 2nd Degree Internal Hemorrhoids

INTRODUCTION:

Arshas/ Hemorrhoids have been a annoyance for the humans, from time unknown.. Hemorrhoids are dilated veins in the anal canal in the sub epithelial region formed by radicles of superior, middle and inferior rectal vein ¹. In *Ayurveda*, Since *Vedic* period

Arshas was the main area of concern among ano-rectal disorders. *Arshas* is considered as one among the eight mahagada and is difficult to cure².it is a local manifestation of systemic derangement of *dosha*. Vitiation of *doshas* adversely affects the digestive fire resulting in *mandagni*⁶, which in

turn leads to constipation. Prolonged contact of accumulated *mala* vitiates *gudavali* resulting in *Arshas*⁶. Bleeding and prolapsed the two main complaints for which the patient of hemorrhoids usually approach for a medical advice.

Shalya tantra, the integral part of *ayurvedic* system contains detail description of *shasti upkarma*¹⁰. *Alepa* is mainly use for the *saman* of local *kupita Doshas* and reduces sign and symptoms which is detailed explained in *sutrasthana mishrak adhyay*¹¹. Most of the patients need quick relief which can be attained by the use of *local application as a Alepa* rather than the use of internal medications. In case of Hemorrhoids different treatment modalities are available like injection therapy, Infrared coagulation, Cryosurgery, Haemorrhoidectomy, Rubber band ligation³. However the risk of recurrence or developing infection of wound after the surgical procedure is high.

Bhaisaijya *Ratnavali* explains about ***Rajani Lepa***⁹ which contains and ***Sudha ksheer*** (EUPHORBIA NERIFOLIA LINN) and ***Haridra*** (CURCUMA LONGA LINN) which is

used as external application in the management of *Arshas*.

CASE REPORT:

A 39yrs old male patient named Mr, Ganesh Kuduri residence of Koppal, came to OPD of *shalyatantra* dept. with complaints of with complaints of bleeding while passing stool since 15 days, constipation since 6 months, feeling of mass per rectum and reduced spontaneously, since 3 months, clinical proctoscopic examination confirmed the diagnosis 2nd Degree Internal Haemorrhoids at 5 and 11 o'clock position. Initially Patient was approached to allopathic treatment as well as some other *ayurvedic* clinics, tried with oral medication but still patient did not felt satisfaction for above mentioned symptoms. On examination blood pressure was 130/80, pulse rate-72bpm, respiratory rate-20/min, R.S-Clear, CVS and CNS no abnormality detected. After a careful discussion regarding the causative factors we planned for **"Rajani Lepa"** application.

Procedure: Pre-Operative Procedure: Patient was elaborated with all necessary investigations. Inform

ROLE OF "RAJANI LEPA" IN THE MANAGEMENT OF ABHAYANTARA ARSHAS W.S.R TO 2ND DEGREE INTERNAL HEMORRHOIDS-CASE REPORT

consent was taken part preparation and bowel preparation was done.

Operative Procedure: patient was asked to be on lithotomy position , - Under Local anesthesia with all aseptic precautions, part painted and draped, per rectal examination done, Slit proctoscope inserted into anus with lignocaine 2% jelly and Pile masses were identified at 5 and 11 o clock position. - Application of Rajani Lepa done and kept for about 2minutes, - later Washed with normal saline. Finally *YashtimadhuGhruta* anal pack inserted and sterile dressing applied.

Post-Operative Procedures: Patient was under observation for 3 hrs in post operative ward, later he was discharged to home with oral medication.

Discharged with following medicines

- 1.Tab-*Anuloma DS* , *1HS*, after food with normal water.
- 2.Tab-*Triphala guggulu* 250mg BD, after food with normal water.
3. syp *Abhayarista* 2tsp with a 30ml of water BD , after food.

Follow up was called on every week for 2 weeks

RESULTS

During a first visit of follow up patient complained about occasional bleeding and no appearance of mass per rectal during defecation and on proctological examination the pile mass were slight shrunken. And on 2rd visit after 2 week there was no bleeding, and complete shrunken pile masses were found. And other symptoms were also resolved.

DISCUSSION

RAJANI LEPA was applied to 2nd dedegree Internal pile mass which contains *SUDHA KSHEER AND HARIDRA CHURNA* , *SUDHA KSHEER* having a properties of *lekhana*, *tikshana-virechaka*, *kaphanissaraka*, *Laghu*, *Tikshna*, *snigda* . *Guna and Ushna Veerya*, The Latex of *euphorbia nerifolia* facilitated the healing process as evidenced by increase in tensile strength, DNA content, epithelization and angiogenesis⁶.,and antibiotic action, P^H of latex is 5.20 as per reference⁷.

And *HARIDRA CHURNA* having a properties of *Tridosha shamaka*, *Varnya*, *Lekhana*, *Vishagna*, *Krimigna*., *vranashifhaka* , *vranropana* and *Ushna Veerya* analgesic and antimicrobiotics
It was observed that due to above

properties it enhances seization of bleeding and pile mass shrinks. , necrosis of tissue followed by fibrosis of plexus helps in prevention of further dilatation of veins and prevents prolapsed of regional mucosa.

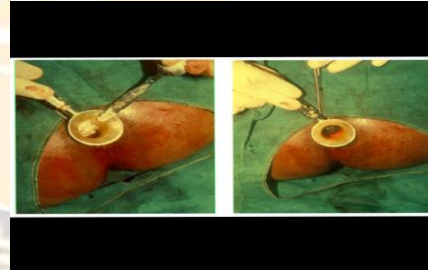
In present day practice application of "**Rajani Lepa**" found better because of its easy availability, and easy to prepare than any "*kshara collection and method of preperation of kshara*" along with that it is safe, efficacious, and cost effective method for 2nd degree internal haemorrhoids.

Conclusion:

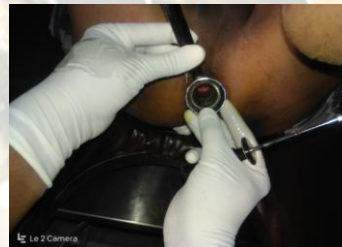Application of *Rajani Lepa* found effective in this 2nd degree internal haemorrhoids within 15days the patient was followed up regularly and by doing proctoscopic examinations in each visit and there is no evidence of recurrence of bleding Haemorrhoid, patient was on active treatment for 2months ,diet restriction followed. Combination of *Rajani Lepa*, conservative treatment, diet restriction and lifestyle modification over a period of 1 year.



2nd degree pile mass with Bleeding



Application of RAJANI LEPA



After complete recovery

REFERENCES

1. S. Das, A Concise Text Book of Surgery, Ed 6, Kolkata, S. Das Publishers2010, pp 1226, p965
2. Acharya Y. T., *Sushruta Samhita*, Ed 8,Varanasi, Chowkhamba *Sanskrit sansthan*2005, Su 33/4, pp 824, p 144
3. Goligher J, Duthie H, Nixon H. Surgery of the Anus, rectum and colon. Vol-1 Newdelhi:A.I.T.B.S. Publishers and distributors;2004. Page-137-9.

4. Acharya J T and Acharya N R 2013, *Sushruta Samhita with Nibandhasangraha* commentary of Shree Dalhanacharya, Varanasi, India: Choukambha Sanskrit samsthan, page no-45 (Sanskrit).
5. Paradkar HS, editor, *Astanga hrudaya*, Varanasi: Choukambha Surabharati prakashan; 2007 page no-643.
6. Recent trends in the management of arshas/ Haemorrhoids. By Dr.P. HemanthKumar. Sanskrit Pratistana, Second Revised Eddition 2011. Total page 179 (Page 14)
7. <https://easyayurveda.com/2017/04/16/snuhi-euphorbia-neriifolia-uses/>
8. <https://www.sciencedirect.com/science/article/pii/S199576451730354>
9. Kaviraj Dr. Ambika Dutta Shastry – "Bhaisajya Ratnavali", Chikitsa stana 9/13, 2014 Chaukhamba Sanskrit santhan publishers Varanasi, page no 577.
10. Sushruta Samhita, edited with Ayurveda Tatva Sandipika by Kaviraja Ambika Dutta Shastri Chaukhamba Sanskrit Sansthan, Chikitsa sthanam chapter 1/8, page no 4.
11. Sushruta Samhita, edited with Ayurveda Tatva Sandipika by Kaviraja Ambika Dutta Shastri Chaukhamba Sanskrit Sansthan, Chikitsa sthanam chapter 1 /14-16, page no 5

Source of Support: NIL
Conflict of Interest : None declared

Corresponding author:

Dr. Savadi B S

HOD, Post-Graduate scholar, Dept of Shalyatantra, SJG Ayurveda medical college, Koppal, Karnataka
Email: