

FISTULA IN ANO - AN REVIEW

**DR GANAPATHI RAO¹, DR CHANDRAKANTH HALLI²,
DR SUBHOD KAMTHIKAR³,**

¹Ph.D Scholar, Department of PhD Studies in ShalyaTantra, ²Professor & Guide, Department of PhD Studies in ShalyaTantra, N.K.Jabshetty Ayurvedic Medica College & PG Centre, Bidar, Karnataka. ³Associate Professor & Co-Guide, Department of Anaesthesiology, BIDar Institute of Medical Sciences(BRIMS), Bidar, Karnataka.

Abstract

Anorectal diseases have plagued the mankind for centuries. Of them, anorectal abscess and anorectal fistulas form a major group affecting human beings causing pain, inconvenience, discharge and incontinence. For understanding perianal sepsis, knowledge of the anatomy and pathology is mandatory. For planning any treatment strategy, anal sphincter complex and pathology are key factors. Eradication of sepsis and maintenance of continence are the two great challenges to the surgical fraternity. To achieve these goals the management spans from simple observation to complex procedures like the mucosal advancement flaps. The drawbacks of the procedures remain as recurrence and incontinence.

Newer modalities like the fibrin glue, fibrin plug, LIFT procedure and stem cell treatment are being used as the treatment modalities. The present article describes patho-physiology and discusses the various investigative modalities and treatment options for fistula in ano.

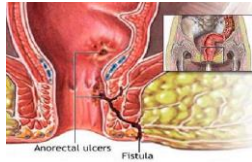
Keywords: Perianal sepsis, fistula in ano, seton, fibrin glue, fibrin plug.

INTRODUCTION

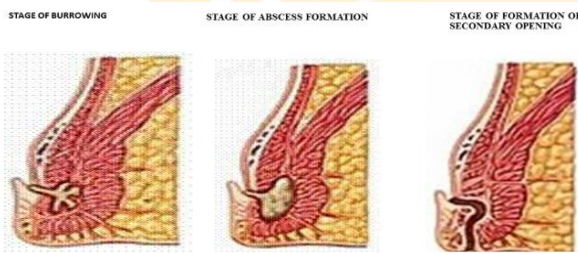
Fistula in ano and ano rectal sepsis is an along established condition described in "Corpus Hippocraticum" in a treatise named "ON- Fistula"¹. Centuries have passed but the basic principles of management of anorectal sepsis

remained the same which revolves around resolution of anorectal sepsis and treatment of fistula without hampering continence. Advent of antibiotics and drainage procedures has led to adequate management of anorectal sepsis but preservation of

continence still remains a challenge and efforts are on to achieve an optimal treatment which attains both leading to improvement in patient care.



PATHOPHYSIOLOGY OF ANO-RECTAL SEPSIS



Understanding the pathophysiology is one of the pivots in management of Anorectal sepsis. Widely accepted crypto glandular theory leading to abscess formation and fistula development needs to be well understood as this is the pathology responsible for almost 90% of the perineal sepsis and anal fistulas. The obstruction of anal crypt gland with inspissated debris leads to infection in these glands, which penetrate, into the anal complex in varying degrees and suppuration follows the path of least resistance. In context to spread of infection, understanding the perineal and anal anatomy is must. As the abscess collects in anatomical spaces

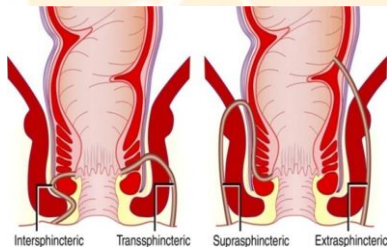
where the anal gland terminates and from there on follows in the perineal spaces. It needs to be emphasized that Anorectal abscess is an acute manifestation of the crypto-glandular infection and fistula is a chronic sequelae of this infection. Almost one third of the patients who undergo drainage of the Anorectal abscess develop the anal fistula². Any recurrent perineal abscess that occurs at the same site as the previous abscess is also a part of the continuation of the same old process and should be considered as a fistula and should be treated accordingly.

In 10% of the patients, the notable cause of the perineal sepsis is not crypto-glandular infection but it could be inflammatory bowel disease, fungal infection, tubercular infection, neoplasm or trauma. Such fistulas are classified as secondary and known to have a complex nature, requiring non-standard methods of management. There is a need to understand this because their management and outcomes differ in crypto glandular diseases and non crypto-glandular diseases.

CLASSIFICATION OF FISTULA IN ANO:-

Classification of fistula in ano is of immense importance as it gives accurate description of the anatomy of the course of the fistulous tract which is helpful to a surgeon in planning the operative cure of the disease. They are usually classified based on relation to the anal-sphincter complex.

Milligan & Morgan in 1934 classified the fistulas into high fistulas-those in which the internal opening lies above the anorectal ring and low fistulas-those in which the internal opening lies below the anorectal ring. It was a simple classification but was abandoned as the tract information was not forthcoming, leading to recurrences.



Park classified the fistulas into sub-mucosal, inter-sphincteric, supra-sphincteric and extra-sphincteric. These terms are quite informative in relation to the sphincter apparatus.

The submucosal fistula is not involving any sphincter and is simplest to manage.

Intersphincteric fistula traverses through the internal sphincter and are the largest category of the fistulas.

Trans sphincteric fistulas pass through both the internal and external sphincters and are further subdivided into low and high depending on the part of the external sphincter muscle. The low fistulas involve only the outer part of the external sphincter while high fistulas involve greater part of the external sphincter. Incontinence would be a complication of this group.

Supra sphincteric fistula typically arise at the dentate line internally, cross above the internal sphincter but below the puborectalis and exit on to the peritoneal site.

Extra sphincteric fistula are rare and do not involve the sphincter complex. They arise from above the dentate line into the ischio-rectal fossa. These are non cryptogenic in nature and have different management strategies. The drawback of this classification is that it is clinically very difficult to classify them and so the need for classification oriented investigations in form of trans rectal ultrasound or Magnetic resonance imaging of perineum.

INVESTIGATIONS IN FISTULA IN ANO

Investigations in fistula in ano are aimed at formulating a surgical strategy. Digital rectal examination is an important milestone in the assessment of fistulas in ano as localization of internal or primary opening is a must in planning any treatment strategy. The primary crypt palpation is possible digitally in about 90% of the patients. Introduction of hydrogen peroxide from external opening with or without the use of methylene blue is another method of localization of the primary crypt³. 3 D endosonology will help in correctly delineating the tract in 94% of the patients.

MANAGEMENT OF FISTULA IN ANO

Medical management

Medical management is often recommended in patients suffering from inflammatory bowel diseases⁶. Even asymptomatic fistulas can be placed under observation after initial drainage of the suppuration and antibiotic treatment. Specific medical treatment of Crohn's disease and tuberculosis needs to be started after histopathological conformation by

biopsy in both these conditions is mandatory and this histopathology helps in excluding neoplastic diseases.

Setons

Setons are other optional treatment for high trans-sphincteric and anterior trans-sphincteric fistulae in women and they should be used in patients with high probability of incontinence^{7,8}. The materials used for Setons are non absorbable sutures like prolene, penrose drains, rubber bands, vessel loops and silastic catheters. A medicated ayurveda thread called kshar sutra was the earliest known seton described by Sushruta which was linen thread soaked in kshar, an alkaline chemical from plant extracts that has a slight tissue cutting property.

Two types of setons are used for management of fistulas. The cutting setons which incise through the tissue and the non-cutting setons which facilitate the drainage of the tract. It takes 3 weeks to 1 year to cut through the tissue.^{9,10} Use of surgical gloves as a cutting seton was an innovation to prevent repeated change of setons and healing is reported from one month to one year. Non cutting setons were mainly used in chronic sepsis and

chronic diseases like HIV positive patients(AIDS/ Severe anorectal sepsis). Recently Setons have been used in combination with fistulotomy as staged procedure.¹¹ multiple setons are placed through tracts after the basic tracts are removed. Incontinence still continues to complicate the treatment, though they are projected as sphincter saving procedures and the reasons for this could be hard gutter shaped scars, loss of anal canal sensations.¹² The use of setons in modern day practices is restricted to complex and hard to treat fistula which are prone for recurrence. In an unpublished comparative study carried out by us Medicated Seton (Ksharsutra) was compared with Fistulectomy in patients of low fistula in ano. Of 63 patients, 56 males and 7 females, with a mean age 38.40 yrs. Fistulectomy group had 31 patients & Medicated Seton (Ksharsutra) group had 32 patients, were well matched for demographic data and fistula characteristics defined on MRI scan (excluding supra sphincteric fistula. The mean healing duration was similar in both groups. Recurrence was 8% in seton group against none in

Fistulectomy group. Incontinence was not seen in both group.

Surgical management Fistulotomy

This is the standard treatment for low simple anal fistulas, submucosal and low inter-sphincteric fistulas.¹³ The indications are low cryptoglandular fistulas, low chronic fistulas, simple fistulas where 30-50% of the tracts pass through the sphincter, which is not anterior in female, single tract, non recurrent, continent, non chronic,. Fistulotomy is usually a single stage procedure but in complex procedures it can be used as a staged procedure with adjuvant seton or glue therapy. The incontinence rate varies from 0-40% in low inter-sphincteric fistulas ¹⁴.

Radiation ablation of tract is another improvement in techniques of fistulectomy. It is known to have decreased gas continence as radiation frequency ablation causes minimal damage to surrounding tissue¹⁵.

Ultrasound dissection of the fistulous tract is a future advancement. The recurrence rate of fistulotomy is 7-16% after 2 yrs follow up. This recurrence rate increases to 40% after 6 yrs. ¹⁶ Fistulotomy forms an important part of fistula management

despite the high rate of incontinence and recurrence.

Fistulectomy

Studies have shown that the Fistulectomy does not offer any additional advantage over the Fistulotomy procedure.

NEWER MODALITIES

1. Fibrin Glue- it is a mixture of fibrinogen, thrombin and calcium ions which when combined form a soluble clot due to cleavage of fibrinogen to fibrin. This clot seals the fistula tract in 30- 60 seconds. Between days 7 and 14 the tract is replaced by synthesized collagen.¹⁸ Success rates of this procedure ranges from 31-85%^{17,19}. The reasons for failure have been quoted to be dislodgement (caused by inadequate removal of granulation tissue) and abscess formation due to lack of complete tract filling with glue.¹⁹ The advantages of this procedure are that it is a simple procedure without any learning curve. There is no decrease in level of continence and also other treatment options remain open in case of a failure.

2. Fibrin Plug- Since its first introduction in 2006 by Robb & colleagues, it has achieved a wide range of success from

14% to 87%.²⁰ The plug is made up of lyophilized porcine small intestinal submucosa shaped in a conical fashion which increases the mechanical stability thus avoiding dislodgement during straining.

The reasons for failure of the plug are improper securing of the plug to the primary opening leading to dislodgement. Multiple fistula tracts have been associated with higher failure rates.²¹

3. Adipose derived stem cells have been used in the treatment of complex anal fistulas. On comparison with fibrin glue, the results have been promising with a recurrence rate of 17% at one year follow-up.

4. Mucosal Advancement Flap- this a sphincter sparing procedure where endorectal/ endoanal flaps are advanced to close the internal ring with or without closure of the tract. Healing rate varies from 77-100%.²² Recurrence rate was noted to be 23%.

Van Koperen and colleagues used the setons to drain the tracts followed by flap advancement with good results.²³ Combining fibrin glue in conjugation with advancement flap has been shown to be a failure in a study conducted by Ellis and Clarke²⁴.

5. **LIFT procedure**- It is ligation of the inter sphincteric fistula tract first described by Rojanasakul in Thailand. The reported success rate of the procedure was 58% 25.

SUMMARY

The management of anorectal sepsis and fistula in ano needs complete knowledge of perineal anatomy and pathophysiology. The sphincter complex is the nodal factor and the type of pathology is important. The first line management should be sphincter saving where sphincter division is avoided. Aggressive surgical approach is only considered when above modalities fail. Newer modalities also need to be evaluated.

BIBLIOGRAPHY

1. **Abbas Ma Lemus**- rangel hamadini A Long term outcome of endorectal advancement flap for complex anorectal fistulae Am Surg 2008 74:921-4.
2. **BuchananGN, WilliamsAM, BartramCI, et al.** Potential clinical implications of directions of a trans-sphincteric anal fistula track. Br J Surg 2003;90:1250– 5.
3. **Buchmann P, Keighley MR, Allan RN, et al.** Natural history of perianal Crohn's disease. Ten-year follow up: a

plea for conservatism. Am J Surg 1980;140:642–4.

4. **CavanaughM, Hyman N, Osler T.** Fecal incontinence severity index after fistulotomy: a predictor of quality of life. Dis Colon Rectum 2002;45:349–53.
5. **DurgunV, perk A, KapanM, et al.** Partial fistulotomy and modified cutting seton procedure in treatment of high extra sphincteric perianal fistulas. Dig surgery 2002;19:56-8.
6. **Ellis CN, Clark S.** Fibrin glue as an adjuvant to flap repair of anal fistulas: a randomized, controlled study. Dis Colon Rectum 2006;49:1736–40.
7. **Gupta P.** Anal fistulotomy with radiofrequency. Dig Surg 2004;21:72–3.
8. **Gonzalez-Ruiz C, Kaiser AM, Vukasin P, et al.** Intraoperative physical diagnosis in the management of anal fistula. Am Surg 2006;72:11–5.
9. **HamalainenKJ, SainioAP.** Cutting setons for anal fistulas: high risk of minor control defects. Dis colon rectum 1997; 40:1443-7.
10. **Hamalainen KJ, Sainio AP.** Cutting setons for anal fistulas: high risk of minor control defects. Dis colon rectum 1997;40:1433-7.

11. **Hammond TM, Graahn MF, Lunniss PJ**, Fibrin glue in the management of the anal fistulae. *Colorectal Dis.* 2004;6:308-19.
12. **Isbister WH, Sanea NA**. The cutting seton- the experience at King Faisal Specialist Hospital Dis colon rectum 2001;44:722-7.
13. **Johnson EK, Gaw JU, Armstrong D**. Efficacy of anal fistula plug vs fibrin glue in closure of Anorectal fistulas. *Dis colon rectum* 2006;49:371-6.
14. **Koperen P, Wind J, Bemelman W, et al.** Long-term functional outcome and risk factors for recurrence after surgical treatment for low and high perianal fistulas of cryptoglandular origin. *Dis Colon Rectum* 2008;51:1475-81.
15. **Lofler T, Welsch T, Muhl S et al.** Long term success rates after surgical treatment of anorectal and rectovaginal fistulas in Chron's disease. *Int Journal Colorectal Disease* 2009;24:521-26.
16. **O'Connor L, Champagne BJ, Ferguson MA, et al.** Efficacy of anal fistula plug in management of Chron's anorectal fistulas. *Dis colon rectum* 2006;49:10:1569-73.
17. **Ratto C, Grillo E, Parello A, et al.** Endoanal ultrasound-guided surgery for anal fistula. *Endoscopy* 2005;37:722-8.
18. **Rojanasakul A.** Total anal sphincter saving technique for fistula-in-ano: the ligation of intersphincteric fistula tract. *J Med Assoc Thai* 2007;90:581-6.
19. **Sentovich SM.** Fibrin glue for all anal fistulas: long term results. *Dis colon rectum* 2003;46:498-502.
20. **Sentovich SM.** Fibrin glue for all anal fistulas. *J Gastrointest Surg* 2001;5:158- 61.
21. **Towsend C, Beauchamp R, Evers B, editors.** Sabiston textbook of surgery: the biological basis of modern surgical practice. 18th edition. Philadelphia: Saunders Elsevier; 2008. pp 1447-9.
22. **Townsend C, Beauchamp R, Evers b, editors.** Sabiston textbook of surgery. 18th edition, Philadelphia, p-1447-9.
23. **Vasilevsky C, Gordon P.** Results of treatment of fistula-in-ano. *Dis Colon Rectum* 1985;28:225-31.
24. **Whiteford M, Kilkenny J, Hyman N et al.** Practice parameters for the treatment of perianal abscess and fistula-in-ano (revised). *Dis Colon Rectum* 2005;48:1337-42.

25. **Zmora O, Neufeld D, Ziv Y et al.** treatment of highly complex cryptogenic fistulae. Dis Colon rectum 2005;7;528-9
Prospective multicentric evaluation of highly concentrated fibrin glue in

Corresponding author:

DR GANAPATHI RAO.I, Ph.D Scholar

Dept. of Ph.D Studies in Shalya Tantra, N.K.J.A.M.C
& P.G.Centre,Bidar-585403

Email: i.ganpathi@gmail.com

Source of Support: NIL

Conflict of Interest : None declared

